

This is an open-access article distributed under the terms of the Creative Commons Attribution License, which permits unrestricted use, distribution, and reproduction in any medium, provided the original author(s) and source are credited.



ISSN:2157-7099

Journal of Cytology & Histology

The International Open Access

Journal of Cytology & Histology

Editor-in-Cheif

George Perry

University of Texas at San Antonio, USA

Executive Editors

Gene P. Siegal

University of Alabama, USA

Bronislaw L Slomiany

University of Medicine and Dentistry of New Jersey, USA

Margaret S Brandwein Gensler

University of Alabama, USA

Dipak K. Dube

SUNY Upstate Medical University, USA

Thorsten Kirsch

New York University School of Medicine, USA

Available online at: OMICS Publishing Group (www.omicsonline.org)

This article was originally published in a journal published by OMICS Publishing Group, and the attached copy is provided by OMICS Publishing Group for the author's benefit and for the benefit of the author's institution, for commercial/research/educational use including without limitation use in instruction at your institution, sending it to specific colleagues that you know, and providing a copy to your institution's administrator.

All other uses, reproduction and distribution, including without limitation commercial reprints, selling or licensing copies or access, or posting on open internet sites, your personal or institution's website or repository, are requested to cite properly.

Digital Object Identifier: <http://dx.doi.org/10.4172/2157-7099.1000167>

Immunohistochemical Evaluation of Bcl-2 Oncoprotein in Buffalo's Adrenal Gland

Hossam Fouad Attia^{1*}, Gamal Hasan Abdel-Rahman², Mohamed Abdu Nassan³, and Ahmed AbdelAziz Baiomy⁴

¹Histology and Cytology Department, Faculty of Veterinary Medicine, Benha University Egypt and Faculty of Applied Medical Science, Taif University KSA

²Zoology department, Faculty of Science, Assuit University Egypt and Faculty of Science, Taif University KSA

³Pathology Department Faculty of Veterinary Medicine Zagazig University Egypt

⁴Zoology department, Faculty of Science, Cairo University Egypt and Faculty of Applied Medical Science, Taif University KSA

Abstract

The present study was undertaken to correlate the immunohistochemical expression of Bcl-2 oncoprotein in buffalo's adrenal gland in the young and old ages. Paraffin-embedded sections from the adrenal glands representing the young and old ages were immunostained for Bcl-2 oncoprotein.

A higher percentage of Bcl-2 immunoreactivity was detected in the adrenal cortical cells of the buffaloes at young ages. The immunoreactivity was moderate in the adrenal cortical cells of the old ages. The degree of intensity was prominent in the zona reticularis than that of the other zones, while negative immunoreactivity in the cells of the adrenal medulla.

In conclusion, the immunohistochemical expression of Bcl-2 oncoprotein in the young buffalo's adrenal gland (antiapoptotic gene) was prominent than the old ages. So the incidence of apoptosis was prominent in the adrenal gland cortical cells of the old age than that the adrenal gland cortical cells of the young ages.

Keywords: Buffalo-bcl-2-adrenal gland; Immunohistochemical; Oncoprotein

Introduction

The adrenal gland consists of cortex and medulla. The adrenal cortex is composed of three concentric layers: the zona glomerulosa, the zona fasciculata, and the zona reticularis, all of which present different morphological and functional properties. Zona glomerulosa is specialized in the production of aldosterone while, zona fasciculata/reticularis synthesize cortisol in humans and bovine, and corticosterone in rodents [1].

Bcl-2 is a human proto-oncogene located on chromosome 18, have been categorized as oncogenes [2], suppressor genes [3] or genes considered to regulate programmed cell death. The Bcl-2 proto-oncogene, first discovered in B cell lymphomas with chromosomal translocation t(14;18) (q32;q21), [4] is associated with the development of lymphoma [5].

The protein product of Bcl-2 is associated with mitochondria [6] and located on outer mitochondrial membranes, the endoplasmic reticulum, and the nuclear envelope [5].

The Bcl-2 oncoprotein is thought to regulate programmed cell death and to facilitate cell survival [7]. It is topographically restricted to cells in proliferating zones and cells with long life spans, and it is down-regulated in terminally differentiating cells.

The main function of the Bcl-2 family is likely to protect mitochondrial integrity and to regulate the release into the cytoplasm of mitochondrial proteins that are involved in the apoptotic pathway, such as cytochrome c [8].

The expression pattern of the Bcl-2 family differs depending on the cell type or stage of differentiation [9]. Moreover, their relative abundance may influence the cellular sensibility to undergo apoptosis in response to a given stimulus (i.e. glucocorticoids). On the other hand, these proteins would be the target for external signals that regulate programmed cell death.

The current study, therefore aimed primary to investigate the

immunohistochemical expression of Bcl-2 oncoprotein in buffalo's adrenal gland at different ages.

Material and Methods

Animals and tissues

14 (7 males and 7 females), buffaloes (*Bubalus bubalis*) adrenal glands were collected from Toukh abattoir in kalyobia governorates, Egypt. Their ages were ranged from 1-12 years and their weight ranges from 100-350 kgs. Specimens were immersed overnight in Bouin's fluid, dehydrated in a graded series of ethanol, cleared in xylene, embedded in Paraplast wax (Sigma-Aldrich, St. Louis, MO, USA) and sectioned at 4 µm thickness. Tissue sections were mounted on positively charged, coated slides (Thermo Scientific, Menzel-Gläser, Braunschweig, Germany).

Materials

Rabbit polyclonal antibody (Sigma Laboratories). Universal kit used avidin biotin peroxidase system produced by (NovaCastra Laboratories Ltd), UK. It was purchased from WAKO Pharmaceutical Company, Tokyo.

Immunohistochemical localization

Immunohistochemical staining for detection of Bcl-2 protein (antiapoptotic marker) was done according to [10].

***Corresponding author:** Hossam Fouad Attia, Histology and Cytology Department, Faculty of Veterinary Medicine, Benha University Egypt and Faculty of Applied Medical Science, Taif University KSA, E-mail: hfh-hosam@hotmail.com

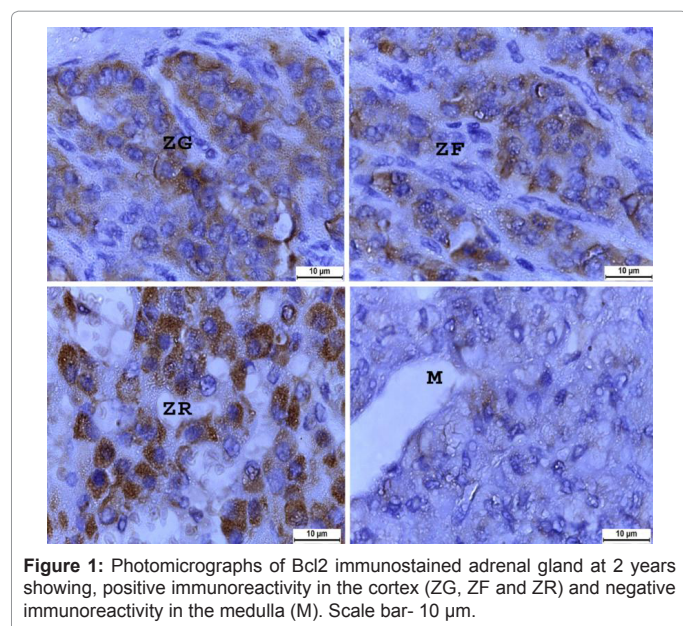
Received December 27, 2012; **Accepted** February 04, 2013; **Published** February 06, 2013

Citation: Attia HF, Abdel-Rahman GH, Nassan MA, Baiomy AA (2013) Immunohistochemical Evaluation of Bcl-2 Oncoprotein in Buffalo's Adrenal Gland. J Cytol Histol 4: 167. doi:10.4172/2157-7099.1000167

Copyright: © 2013 Attia HF, et al. This is an open-access article distributed under the terms of the Creative Commons Attribution License, which permits unrestricted use, distribution, and reproduction in any medium, provided the original author and source are credited.

	Young ages	Old ages
Zona glomerularis	35.0 ± 1.58	21.8 ± 1.64
Zona fasciculata	40.6 ± 1.48	30.6 ± 1.79
Zona reticularis	49.4 ± 2.60	38.0 ± 1.98
Medulla	0	0

Table 1: Numerical values (means ± SD) of immunostained cells in the buffalo's adrenal glands at young and old ages.



Immunohistochemical reaction was carried using avidin biotin peroxidase system. The primary antibody used was a rabbit polyclonal antibody (Sigma Laboratories) at a dilution of 1:100 was used. Universal kit used avidin biotin peroxidase system produced by NovaCastra Laboratories Ltd, UK. The same method was applied to prepare negative control sections but the primary antibody was not added. Mayer's hematoxylin was added as counter stain. Tonsil was used as positive control tissue. Finally, the Bcl-2 cytoplasmic site of reaction was stained brown and nuclei stained blue. This technique was done in the institute of tumours, Cairo University. Digital photomicrographs were taken using an imaging system consisting of light microscope (Leica DM LB, Leica Microsystems, Wetzlar, Germany) and digital camera (Leica EC3, Leica Microsystems).

The immunostained cells in the adrenal cortex and medulla were counted in 5 different tissue sections for each age group. For each section, cells were counted in 10 fields (x10) and the mean values for each section were calculated. The numbers (means ± SD) of cells were then calculated for each age group (Table 1).

Results

Immunohistochemical analysis with polyclonal antibodies to Bcl-2 oncoprotein in paraffin-embedded tissue sections revealed that a higher percentage of immunoreactivity was detected in the cells of the buffalo's adrenal gland. The adrenal cortex consisted of, zona glomerularis (zona arcuata), zona fasciculata and zona reticularis.

At young ages (1-4 years old), positive immunoreactivity for Bcl-2 was detected in the cells of buffaloes adrenal cortex. The degree of immunoreactivity intensity was strong in zona reticularis then zona fasciculata and lastly in zona glomerularis (zona arcuata). While, negative

immunoreactivity was detected in the cells of the adrenal medulla (Figure 1 and Table 1).

At old ages (10-12 years old), moderate immunoreactivity for Bcl-2 was detected in the cells of the cortex of buffalo's adrenal gland, while negative immunoreactivity in the cells of the adrenal medulla (Figure 2 and Table 1).

Discussion

The Bcl-2 gene, located at chromosome 18q21. It was originally identified by chromosome analysis of the t(14;18) translocation in human follicular lymphoma [4]. The Bcl-2 gene product is a mitochondrial membrane protein. It found also in the nuclear envelope and to a lesser degree in the cell membrane [11], which prevents programmed cell death (apoptosis) [6]. It can be detected by immunostaining in primary lymphoid follicles and in the mantle zone of secondary follicles that largely constitute the homing sites of long-lived memory B-cells [12].

Prominent Bcl-2 staining was observed in the adrenal cortex with a bright intense staining pattern in the zona reticularis and a prominent stippled positive staining in the fasciculata, while the adrenal medulla did not stained positive for Bcl-2 [13]. These findings augmented our findings in the buffalo's adrenal gland however, [14] showed positivity of Bcl-2 staining in both benign adrenal medulla and pheochromocytomas. The authors observed numerous cells of normal adrenal medulla stained positive for Bcl-2 and depict heochromocytomas with perivascular Bcl-2 staining pattern. In addition, the authors reported occasional Bcl-2 positive cells in the adrenal cortex.

Bcl-2 protein also found and expressed in non-lymphoid haematopoietic precursors, such as the early identifiable myeloid cells [15], duct cells of exocrine glands, uterine smooth muscle, endometrial glands, thyroid follicles, prostatic glands and breast lobules [16].

The detection of Bcl-2 protein in fetal epithelial germinative regions, in placental trophoblast, as well as endocrine cells and neurons, suggests

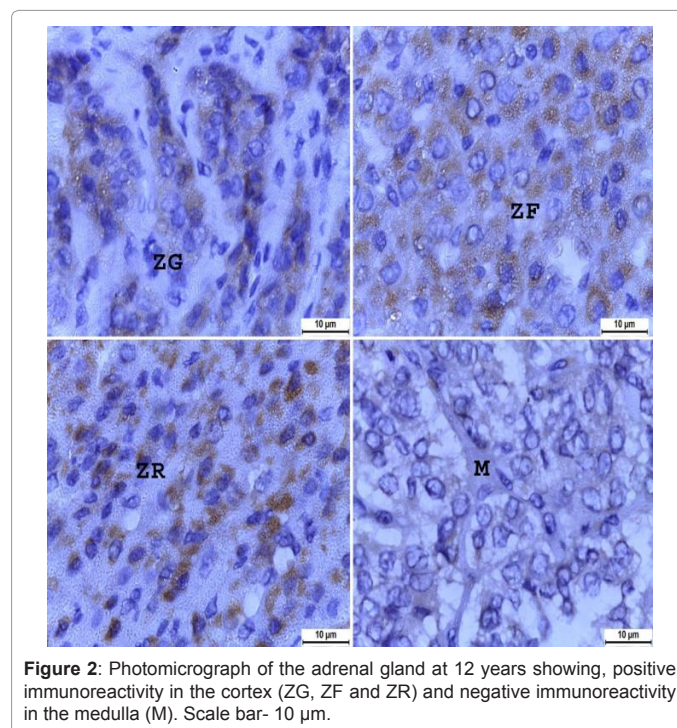


Figure 2: Photomicrograph of the adrenal gland at 12 years showing, positive immunoreactivity in the cortex (ZG, ZF and ZR) and negative immunoreactivity in the medulla (M). Scale bar- 10 µm.

that this protein may play a regulatory role in normal homeostasis of both developing and established tissues. Expression of Bcl-2 protein apparently serves to maintain cells in the tissues, by avoiding cellular senescence and death.

In addition, Bcl-2 protein is involved in morphogenesis by inducing interactions between epithelia and mesenchyme, contributing to the formation of condensations of cells that are "committed" to develop more differentiated structures [16].

Bcl-2 has also been found to promote survival in response to a wide variety of cell stresses and cytotoxic chemicals, including heat shock, ionizing radiation, excess calcium influx and a range of chemotherapeutic drugs [17,18].

Apoptosis is a tightly regulated and a highly efficient process that requires the interplay of multiple factors. It can be triggered by various stimuli of diverse origin that converge into common cell death machinery involving the activation of cysteine-dependent aspartate-specific proteases, called caspases [19]. The apoptotic process is regulated at several checkpoints. One of them is mainly controlled by members of the Bcl-2 family [20,21]. Bcl-2 homologues can be defined by the presence of conserved sequence motifs known as Bcl-2 homologous domains (BH1–BH4).

In mammals, more than 30 relatives have been described; some of them belong to the group of anti-apoptotic members (i.e. Bcl-2, Bcl-xL, and Mcl-1 [22], which possess the four BH domains, while other belong to the pro-apoptotic group, such as the Bax-subfamily (Bax, Bak and Bcl-xS [21], which possesses three out of four domains (BH1, BH2 and BH3), and the BH3-only members such as Bid, Bim and Bad which have only the BH3 domain, necessary and sufficient for the killing effect [8,23].

The Bcl-2 protein is a regulator of the apoptotic process, and elevated levels can provide resistance to cell death [24,25]. The Bcl-2 protein is expressed in the interior of cells, frequently localized to the mitochondrial membrane [26,27].

The expression pattern of the Bcl-2 family differs depending on the cell type or stage of differentiation [9]. Moreover, their relative abundance may influence the cellular sensibility to undergo apoptosis in response to a given stimulus (i.e. glucocorticoids). On the other hand, these proteins would be the target for external signals that regulate programmed cell death.

Glucocorticoids control apoptosis in a tissue-specific manner. For instance, these steroids trigger thymocyte apoptosis in a complex process that involves the enhancement of cyclin-dependent kinase 2 activity, the down-regulation of antiapoptotic Bcl-2 protein expression and the up-regulation of the pro-apoptotic Bcl-2 proteins [28], such as the BH3-subfamily member Bad [29].

The adrenal gland, as an organ responding to stress, is subject to dynamic structural changes, including both proliferation as well as cell death. A balance between these two processes is essential for integrity and functionality of this organ. Regulatory systems of the organism and the autocrine and paracrine local networks determine the cell cycle balance [30].

In rat adrenal cortex, the cells composing each zone are continuously renewed by migration of new cells derivate from progenitor cells that differentiate and die. Thus, apoptosis regulation in adrenal gland may be essential for the definition of the functional zonal architecture [31].

Three theories to explain the zonalization of adrenal cortex. The migration theory describes cell proliferation in the cortex outer part, their migration and differentiation from glomerular zone to fascicular zone and from this to reticular zone where the cells degenerate and die. On the other hand, the transformation theory proposes two transformation directions considering the replacement of zonal tissue by proliferant cells. These transformation zones are placed between the glomerular zone and the fascicular zone from which migration takes place in two opposite directions: on one side towards the medulla and on the other towards the capsule. Finally, the zonal theory proposes an equal proliferation in the three zones. Since the apoptosis also takes place in the three cortex zones, each zone could be locally regulated without being affected by other zones. All these theories intend to explain the phenomenon of maintaining structural homeostasis and the relationship between proliferation and programmed cell death [30,32].

Apoptosis might represent a regulatory mechanism of tissue integrity which might allow the organism to face stressing situations as well as functional demands required for replication, differentiation and cellular migration. Thus, the occurrence of the apoptosis in the three adrenal cortex zones might guarantee the independent regulation of all stages of cellular development in the different cytophysiopathologic situations [33].

The cell proliferation indices are the highest in zona glomerularis and in the outer part of zona fasciculata but the lowest in zona reticularis [34]. In contrast, the apoptotic index is the highest in zona reticularis [35]. Although the majority of these studies were performed in rodents, the similar observations concern the human adrenal gland [36]. It is suggested that adrenocortical cells renew from the progenitor cells located in zona glomerularis/zona fasciculata boundary and/or in subcapsular layer.

Suppresses apoptosis in a variety of cell systems including factor-dependent lymphohematopoietic and neural cells. It regulates cell death by controlling the mitochondrial membrane permeability. It appears to function in a feedback loop system with caspases. It inhibits caspase activity either by preventing the release of cytochrome c from the mitochondria and/or by binding to the apoptosis-activating factor (APAF-1) [37].

The Bcl-2 gene product prevents programmed cell death (apoptosis) and possibly promotes tumour development. This protein has mainly been demonstrated in the cytoplasm of various normal and neoplastic cells [38]. This protein also may be involved in adrenal insufficiency in acute necrotizing pancreatitis (ANP). The adrenal injury is attributable to hemorrhagic inflammation, necrosis, and apoptosis of the adrenal cortex [39].

Apoptosis, which plays a central role in both normal cell cycle and tumor biology, is controlled by a family of related proteins. Bcl-2 protein is the main representative of this family, and its role in preventing apoptosis is well known. However, alternative apoptotic pathways have also been found, which are regulated by Bcl-2-like proteins. Some of these proteins, such as Bcl-xL, Mcl-1, Murine Al, Ced 9 and Bag, inhibit apoptotic cell death, whereas others, such as Bcl-xS, Bax, Bad and Bak accelerate apoptosis [40,41].

The expression of Bcl-2 was prominent in the buffalo's adrenal cortical cells of the young ages (incidence of apoptosis was lower), while the expression of Bcl-2 was moderate in the buffalo's adrenal cortical cells of the old ages (incidence of apoptosis was higher).

References

- Rainey WE (1999) Adrenal zonation: clues from 11 β -hydroxylase and aldosterone synthase. *Mol Cell Endocrinol* 151: 151-160.
- Bishop JM (1991) Molecular themes in oncogenesis. *Cell* 64: 235-248.
- Weinberg RA (1991) Tumor suppressor genes. *Science* 254: 1138-1146.
- Tsujimoto Y, Gorham J, Cossman J, Jaffe E, Croce CM (1985) The t(14;18) chromosome translocations involved in B-cell neoplasms result from mistakes in VDJ joining. *Science* 229: 1390-1393.
- McDonnell TJ, Korsmeyer SJ (1991) Progression from lymphoid hyperplasia to high-grade malignant lymphoma in mice transgenic for the t(14; 18). *Nature* 349: 254-256.
- Hockenbery D, Nuñez G, Millman C, Schreiber RD, Korsmeyer SJ (1990) Bcl-2 is an inner mitochondrial membrane protein that blocks programmed cell death. *Nature* 348: 334-336.
- Castle VP, Heidelberger KP, Bromberg J, Ou X, Dole M, et al. (1993) Expression of the apoptosis-suppressing protein bcl-2, in neuroblastoma is associated with unfavorable histology and N-myc amplification. *Am J Pathol* 143: 1543-1550.
- Cory S, Adams JM (2002) The Bcl2 family: regulators of the cellular life-or-death switch. *Nat Rev Cancer* 2: 647-656.
- Reed JC (2003) Apoptosis-targeted therapies for cancer. *Cancer Cell* 3: 17-22.
- Kiernan JA (2008) *Histological and Histochemical Methods: Theory and Practice*. (4th edn), Bloxham: Scion.
- van Slooten HJ, Claassen PC, van Dierendonck JH, Duval C, Pallud C, et al. (1996) Expression of Bcl-2 in node-negative breast cancer is associated with various prognostic factors, but does not predict response to one course of perioperative chemotherapy. *Br J Cancer* 74: 78-85.
- Pezzella F, Tse AG, Cordell JL, Pulford KA, Gatter KC, et al. (1990) Expression of the bcl-2 oncogene protein is not specific for the 14;18 chromosomal translocation. *Am J Pathol* 137: 225-232.
- Fogt F, Vortmeyer AO, Poremba C, Minda M, Harris CA, et al. (1998) bcl-2 expression in normal adrenal glands and in adrenal neoplasms. *Mod Pathol* 11: 716-720.
- Clarke MR, Weyant RJ, Watson CG, Carty SE (1998) Prognostic markers in pheochromocytoma. *Hum Pathol* 29: 522-526.
- Zutter M, Hockenbery D, Silverman GA, Korsmeyer SJ (1991) Immunolocalization of the Bcl-2 protein within hematopoietic neoplasms. *Blood* 78: 1062-1068.
- LeBrun DP, Warnke RA, Cleary ML (1993) Expression of bcl-2 in fetal tissues suggests a role in morphogenesis. *Am J Pathol* 142: 743-753.
- Lotem J, Sachs L (1993) Regulation by bcl-2, c-myc, and p53 of susceptibility to induction of apoptosis by heat shock and cancer chemotherapy compounds in differentiation-competent and -defective myeloid leukemic cells. *Cell Growth Differ* 4: 41-47.
- McConkey DJ, Nicotera P, Hartzell P, Bellomo G, Willey AH, et al. (1989) Glucocorticoids activate a suicide process in thymocytes through an elevation of cytosolic Ca²⁺ concentration. *Arch Biochem Biophys* 269: 365-370.
- Green DR (1998) Apoptotic pathways: the roads to ruin. *Cell* 94: 695-698.
- Green DR, Reed JC (1998) Mitochondria and apoptosis. *Science* 281: 1309-1312.
- Gross A, McDonnell JM, Korsmeyer SJ (1999) BCL-2 family members and the mitochondria in apoptosis. *Genes Dev* 13: 1899-1911.
- Adams JM, Cory S (1998) The Bcl-2 protein family: arbiters of cell survival. *Science* 281: 1322-1326.
- Mund T, Gewies A, Schoenfeld N, Bauer MK, Grimm S (2003) Spike, a novel BH3-only protein, regulates apoptosis at the endoplasmic reticulum. *FASEB J* 17: 696-698.
- Reed JC (1997) Double identity for proteins of the Bcl-2 family. *Nature* 387: 773-776.
- Digiuseppe JA, LeBeau P, Augenbraun J, Borowitz MJ (1996) Multiparameter flow-cytometric analysis of bcl-2 and Fas expression in normal and neoplastic hematopoiesis. *Am J Clin Pathol* 106: 345-351.
- Krajewski S, Tanaka S, Takayama S, Schibler MJ, Fenton W, et al. (1993) Investigation of the subcellular distribution of the bcl-2 oncoprotein: residence in the nuclear envelope, endoplasmic reticulum, and outer mitochondrial membranes. *Cancer Res* 53: 4701-4714.
- Zamai L, Canonico B, Gritzapis A, Luchetti F, Felici C, et al. (2002) Intracellular detection of Bcl-2 and p53 proteins by flow cytometry: comparison of monoclonal antibodies and sample preparation protocols. *J Biol Regul Homeost Agents* 16: 289-302.
- Lépine S, Sulpice JC, Giraud F (2005) Signaling pathways involved in glucocorticoid-induced apoptosis of thymocytes. *Crit Rev Immunol* 25: 263-288.
- Mok CL, Gil-Gómez G, Williams O, Coles M, Taga S, et al. (1999) Bad can act as a key regulator of T cell apoptosis and T cell development. *J Exp Med* 189: 575-586.
- Wolkersdörfer GW, Bornstein SR (1998) Tissue remodelling in the adrenal gland. *Biochem Pharmacol* 56: 163-171.
- Mitani F, Suzuki H, Hata J, Ogishima T, Shimada H, et al. (1994) A novel cell layer without corticosteroid-synthesizing enzymes in rat adrenal cortex: histochemical detection and possible physiological role. *Endocrinology* 135: 431-438.
- Kaczmarczyk D, Kmiec BL, Daczewska M, Kmiec KB (2004) Proliferation and apoptosis in the guinea pig adrenal cortex during postnatal development. *Folia Morphol (Warsz)* 63: 333-335.
- Bozzo A, Soñez CA, Mugnaini MT, Pastorino IC, Rolando AN, et al. (2006) Chronic stress effects on the apoptotic index of the adrenal cortex of pregnant rats. *Biocell* v.30 n.3.
- Pawlikowski M, Gruszka A, Mucha S, Melen-Mucha G (2001) Angiotensins II and IV stimulate the rat adrenocortical cell proliferation acting via different receptors. *Endocr Regul* 35: 139-142.
- Carsia RV, MacDonald GJ, Gibney JA, Tilly KI, Tilly JL (1996) Apoptotic cell death in the rat adrenal gland: an in vivo and in vitro investigation. *Cell Tissue Res* 283: 247-254.
- Sasano H, Imatani A, Shizawa S, Suzuki T, Nagura H (1995) Cell proliferation and apoptosis in normal and pathologic human adrenal. *Mod Pathol* 8: 11-17.
- Wei Y, Pattingre S, Sinha S, Bassik M, Levine B (2008) JNK1-mediated phosphorylation of Bcl-2 regulates starvation-induced autophagy. *Mol Cell* 30: 678-688.
- Papadimitriou CS, Costopoulos JS, Christoforidou BP, Kotsianti AJ, Karkavelas GS, et al. (1997) Expression of Bcl-2 protein in human primary breast carcinomas and its correlation with multifocality, histopathological types and prognosis. *Eur J Cancer* 33: 1275-1280.
- Yu J, Xu S, Wang WX, Deng WH, Jin H, et al. (2012) Changes of inflammation and apoptosis in adrenal gland after experimental injury in rats with acute necrotizing pancreatitis. *Inflammation* 35: 11-22.
- Bargou RC, Daniel PT, Mapara MY, Bommert K, Wagener C, et al. (1995) Expression of the bcl-2 gene family in normal and malignant breast tissue: low bax-alpha expression in tumor cells correlates with resistance towards apoptosis. *Int J Cancer* 60: 854-859.
- Kernohan NM, Cox LS (1996) Regulation of apoptosis by Bcl-2 and its related proteins: immunochemical challenges and therapeutic implications. *J Pathol* 179: 1-3.

Citation: Attia HF, Abdel-Rahman GH, Nassan MA, Baiomy AA (2013) Immunohistochemical Evaluation of Bcl-2 Oncoprotein in Buffalo's Adrenal Gland. *J Cytol Histol* 4: 167. doi:[10.4172/2157-7099.1000167](https://doi.org/10.4172/2157-7099.1000167)